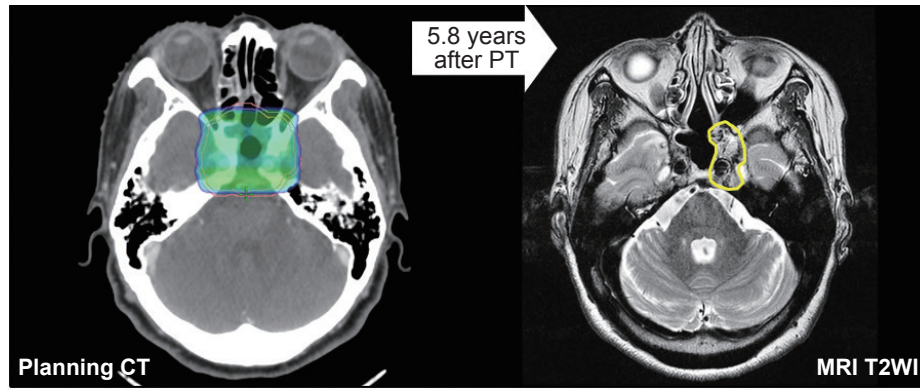


## Supplementary Materials



**Fig. S1.** Diagnostic axial magnetic resonance images at the time of local failure and corresponding planning CT images with 95% isodose distribution: a 57-year-old female patient with the skull base chordoma. Yellow-line indicates contour for the recurrent lesions; CT, computed tomography; MRI T2WI, axial T2-weighted image on magnetic resonance imaging.