

Supplementary Materials

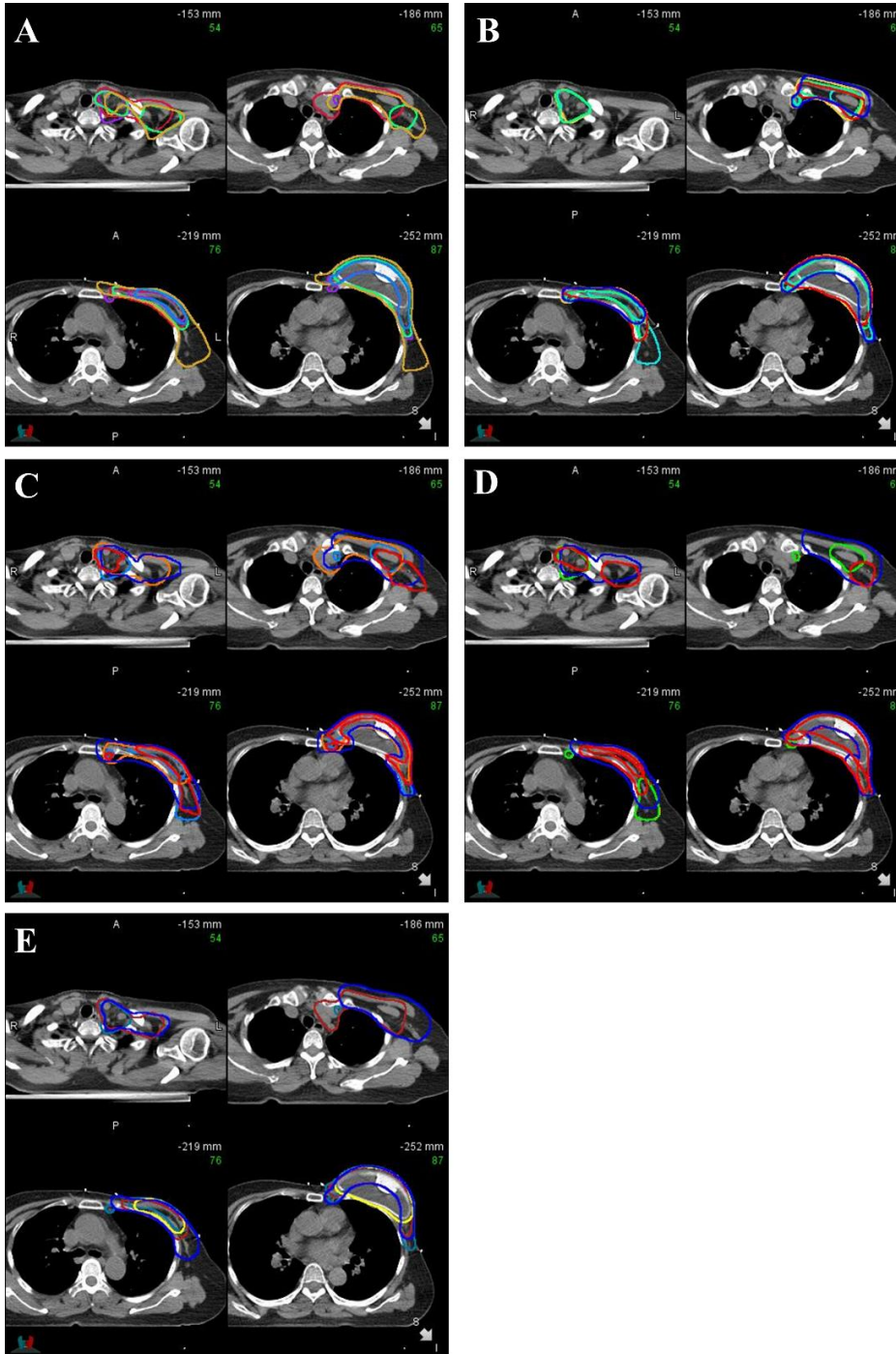


Fig. S1. Radiation therapy structures included according to each clinical scenario. (A) Case 1: pT2N (3/12). (B) Case 2: pT3N (7/22) with pathologic axillar level 1 node positive. (C) Case 3: icN3 (internal mammary node positive) → ypT2N (5/15). (D) Case 4: pT2N (5/22) with pre-pectoral reconstruction. (E) Case 5: pT2N (3/16) with positive resection margin.